

<https://doi.org/10.35339/msz.2020.89.04.04>
UDC 612.44.014:616.441-71-089

O.V. Fedosieieva

Zaporizhzhia State Medical University, Ukraine

THE FEATURES OF PROLIFERATIVE PROCESSES IN THE THYROID GLAND OF THE WISTAR RAT'S OFFSPRING AFTER INTRAUTERINE ACTION OF DEXAMETHASONE

The features of proliferative processes in the thyroid gland of the Wistar rat's offspring after intrauterine action of dexamethasone were studied. Animals were divided into 3 groups: I – intact rats; II – control – animals, which on the 18th day of the dated pregnancy transuterine, transdermal, subcutaneously in the interscapular area was injected with 0.9 % saline in the amount of 0.05 ml; III – experimental group – animals, which during laparotomy by intrauterine, transdermal subcutaneous injection in the interscapular area was injected with a solution of dexamethasone at a dose of 0.05 ml at a dilution of 1:40 intrauterinely on the 18th day of pregnancy (Ukrainian patent № 112288). In the experimental subgroups used the allowable, generally accepted number of animals for statistical processing and obtaining reliable results – 6 animals. The thyroid gland with the tracheal area was removed on the 21st, 30th, 45th, 60th, 90th, 120th days of life. Immunohistochemical study was performed according to the protocol recommended for a particular antibody manufacturer. Monoclonal antibodies ki-67 (Ki-67), Fox-1 Antibody (A-12) were used to assess proliferative activity, the company Santa Cruz Biotechnology, Inc. (USA). The study found that the thyroid gland of rats of infantile period, which prenatally exposed to dexamethasone, is structurally represented by chaotically located follicles of different diameters with a predominance of large with desquamated cells in the lumen, and proliferative changes aimed at forming extrafollicular which is confirmed immunohistochemically by the presence of Ki-67-positive cells. Intracellularly, protein-synthesizing organelles of thyrocytes also proliferate, to which there is a clear cytoplasmic and nuclear reaction with Fox-1 antibodies. During the juvenile period, proliferative processes in the thyroid gland of animals of the experimental group are stabilized while maintaining the morphological structure of the hypofunctional type, and remain lower compared to the control and intact groups. Morphological signs of functional tension of the thyroid gland animals exposed prenatally to dexamethasone, which correlate with a decrease in proliferative activity, indicate a functional compensatory response of synthetic and hormone-producing function, but suppression of proliferative processes, despite the slight manifestations. The thyroid gland of morphological hypofunctional type after prenatal action of dexamethasone in young rats, indicates an adaptogenic compensatory response and morphofunctional immaturity of the organ during this period, which may be the basis for provoking the preservation of such morphogenetic factors under the influence of stressors.

Keywords: *thyroid gland, proliferation, dexamethasone, experiment, rats.*

Introduction

The urgency of the problem of thyroid disease in children and adolescents in Ukraine has existed

for a long time. Pathology of the thyroid gland in recent years has become the number one endocrine disease in children in Ukraine, and it

© O.V. Fedosieieva, 2020

forms the picture of the prevalence of all endocrine diseases, as it occupies more than 50 % of their structure, mainly due to disorders of organ morphogenesis and immune neuroneurosis, endocrine imbalance [1, 2]. In clinical practice, synthetic glucocorticoids such as dexamethasone are used to accelerate fetal maturation in pregnant women at risk of preterm birth. In humans and other mammals, a surge of cortisol in the body causes structural and functional changes in the tissues of the fetus, preparing it for childbirth and extrauterine life, but they can have long-term consequences in the structural organization of organs remotely postnatally [3–8]. Unfortunately, despite the large number of studies on the effects of glucocorticoids on the fetus, there is almost no data on the prenatal effect of dexamethasone on the processes of proliferation in the thyroid gland. Thus, the question of prenatal influence of dexamethasone on the processes of thyroid proliferation in the postnatal period of life is morphologically unresolved, and needs further scientific clarification, which is an extremely important experimental basis for improving the management of neonates, infants and children endocrinologists.

The purpose of the study was to establish the features of proliferative processes in the thyroid gland of rats in the age periods after prenatal exposure of dexamethasone.

Material and Methods

The study involved the thyroid glands of 108 white laboratory Wistar rats from 21 to 120 days of age. The animals were obtained from the vivarium of PE «Biomodelservice» in Kyiv. Rats were kept in a vivarium in acrylic cages with a volume of 300 cm³ for 4–5 animals each and free access to water on a standard diet. Before and during the experiment the rats were in the same conditions: in the vivarium at t 20–25 °C, humidity not more than 50 %, the volume of air exchange (extract-inflow) 8:10, in the light mode day and night. The animals were healthy in behavior and general condition. The conditions of care for animals complied with the norms of the «International Recommendations for Medical and Biological Research with the Use of Animals». The work also followed the rules and regulations established by the «European Convention for the Protection of Vertebrate Animals Used for Experimental and Other Scientific Purposes» (Strasbourg, 18.03.86) and the Law of Ukraine «On

Protection of Animals from Cruelty» (from 21.02.06 № 3447-IV, edition of 09.12.15, grounds 766-19).

Animals were divided into three groups: Group I – intact rats; Group II – control – animals, which on the 18th day of the dated pregnancy transuterine, transdermal, subcutaneously in the interscapular area was injected with 0.9 % saline in the amount of 0.05 ml; III – experimental group – animals, which during laparotomy by intrauterine, transdermal subcutaneous injection in the interscapular area was injected with a solution of dexamethasone at a dose of 0.05 ml at a dilution of 1:40 on the 18th day of pregnancy (Ukrainian patent № 112288). In the experimental subgroups used the allowable, generally accepted number of animals for statistical processing and obtaining reliable results – 6 animals.

For the convenience of interpretation, generalization and extrapolation of the obtained results of the study of animals of the corresponding life spans were grouped by age periodization [9]: infantile (late dairy) period – 21st–50th days; premarital (juvenile) period – 51st–120th days.

The thyroid gland with the tracheal area was removed on the 21st, 30th, 45th, 60th, 90th, 120th days of life, fixed in a 10 % solution of neutral buffered formalin during the day. The objects were filled into paraffin blocks by the conventional method. Histological sections with a thickness of 4 µm were stained with hematoxylin and eosin for observation light microscopy and morphometry, histochemically with azan to determine the density of the colloid. The number of cells was counted in histological sections in a standardized field of view of the microscope at magnification × 40 (number of cells per 40,000 µm²), followed by calculation of the cell density per 1 mm².

Immunohistochemical study was performed according to the protocol recommended for a particular antibody manufacturer. Monoclonal antibodies ki-67 (Ki-67), Fox-1 Antibody (A-12) were used to assess proliferative activity, the company Santa Cruz Biotechnology, Inc. (USA) using the method of indirect staining with immunoperoxidase using conjugated HRP murine IgG-binding proteins, m-IgGκ BP-HRP, followed by incubation in a substrate of peroxidase and a mixture of chromogen DAB-3-diaminobenzidine tetrachloride and hemp dyeing enlightenment and confinement in balm.

The result was regarded as positive in the precipitation of chromogen salts in the form of a

specific reaction (nuclear, cytoplasmic reaction depending on the location of the antigen). The intensity of benzidine label deposition was evaluated in points according to the following gradation: 0 – no reaction, light yellow color; 1 – weak reaction – light brown color; 2 – moderate reaction – brown color; 3 – intense reaction – dark brown color. Intermediate shades denoted 0.5; 1.5 and 2.5 points, respectively.

In order to control the method a series of studies was conducted using positive and negative samples, which served as standards.

Morphometry and photodocumentation of the studied objects were performed using a Primo Star microscope (Carl Zeiss, Germany) using an AxioCam camera, a set of morphometric studies was performed using the Zeiss Zen program (2011).

Statistical analysis of the results was performed using a personal computer based on the Windows XP operating system using the statistical package Statistica for Windows 6.0 (StatSoft, Inc.), Excel (Microsoft Office, USA). All research results were recorded in journals and protocols of primary documentation, as well as with the use of electronic media. The hypothesis about the normality of the distribution of the studied indicators was tested using the Shapiro–Wilk test. The median, lower and upper quartiles were calculated, and the data were presented as Me (Q1; Q3). Significance of differences between means was assessed using Student's parametric t-test at normal and considered statistically significant at a confidence level of at least 95 %. For all types of analysis, the differences were considered significant at $p < 0.05$.

Results and Discussions

Infantile (late dairy) period. On the 21st day the number of light thyrocytes increased compared to the groups of intact and control, which indicates the differentiation of cells into active hormone-producing. Clearly, this process is a compensatory response to morphological manifestations of hypofunction of the thyroid gland, which correlated with the height of thyrocytes. On day 30th of postnatal life, large follicles with flattened thyrocytes, desquamated cells, and dense colloid without resorption vacuoles were subcapsularly visualized in the thyroid glands of animals prenatally exposed to dexamethasone. In the part of the follicles lined with cubic thyrocytes, the colloid was absent. The number of microfollicles became smaller, and the proportion of proliferating Ki-67-positive cells in

the wall of the follicles decreased insignificantly compared to the previous period, but compared to the control of proliferating cells was 1.8 times less. In the wall of the follicle there were much more light thyrocytes, which usually contained a large structured nucleus, in which 2–3 nucleoli were visualized. The height of thyrocytes decreased compared to the control and was 6.58 (3.75; 7.87) μm and 7.12 (5.69; 7.80) μm , respectively. On days 30–45th of postnatal development in the thyroid glands of rats experimentally prenatally exposed to dexamethasone in the wall of large follicles with flattened epithelium, extrafollicular proliferation of thyrocytes began against the background of visualization in the lumen of these follicles of desquamated cells. In extrafollicular proliferating thyrocytes there was a bright perinuclear and cytoplasmic Fox-1-positive reaction (*fig. 1, a*). This histological picture was throughout the parenchyma of the thyroid gland. In cubic thyrocytes of follicles of colloidal type of Fox-1 secretion, the expression was brightly visualized in the cytoplasm of cells, which is characteristic of the intensification of protein-synthetic processes and intracellular proliferation of synthetic organelles of thyrocytes. At the same time, in the thyroid gland of rats of intact and control groups there was a bright positive cytoplasmic and nuclear expression of Fox-1 antibodies in most follicular thyrocytes (*fig. 1, b*).

Premarital (juvenile) period. On the 60th day of postnatal life the structure of the gland changed in the direction of increasing the manifestations of the process of blocking the excretion of thyroid hormones, but the synthesis and excretion of components into the follicle cavity was preserved. Throughout the body, the follicles enlarged, and large subcapsular follicles were even slightly deformed due to the appearance of intussusception directed into the cavity of the follicles. The average values of thyrocyte height of such follicles were inextricably reduced compared to the control and their median was 5.87 (4.84; 6.38) μm , but their cubic shape was preserved. At the sites of intussusception, the shape of the cells was cubic and single prismatic, Ki-67-positive cells were visualized, resorption vacuoles were absent, and their number was significantly smaller compared to the thyroid glands of intact and control animals. One week after birth in the thyroid glands of experimental animals exposed to dexamethasone

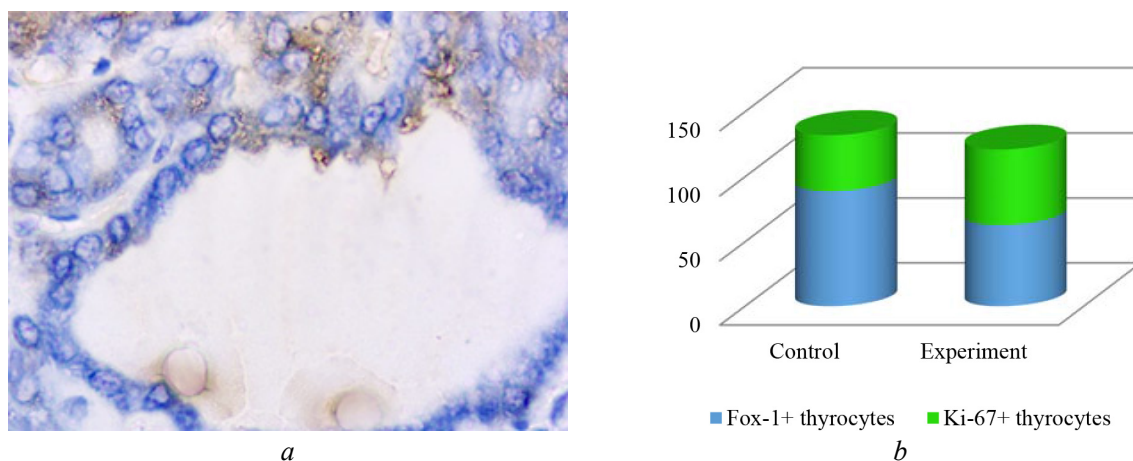


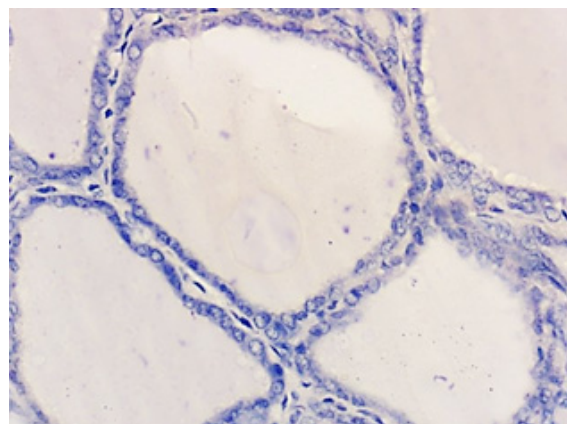
Fig. 1. Cytological profile of proliferative processes in the infantile rat's thyroid gland: *a* – immunohistochemical study with Fox-1 antibodies (arrows indicate a positive cytoplasmic reaction in extrafollicular proliferative clusters of thyrocytes), magnification $\times 400$; *b* – cytological profile of Fox-1 and Ki-67-positive thyrocytes in control group and experimentally prenatally exposed animals with dexamethasone, which reflects intracellular and cellular proliferative processes in the thyroid gland

showed a decrease in the area of the thyroid epithelium. This is due to the fact that the height of the cells of the follicular epithelium becomes smaller, the cubic and flat shape of thyrocytes predominates, cylindrical cells are rare, mainly in small follicles. The increase in the area of the colloid compared to the control was 1.7 times [864 (789.5; 843.6) μm^2] due to the increase in the number of large and medium-sized follicles containing dense, dense colloid and desquamated cells, with no vacuolation of the colloid. On the 60th day of the postnatal period of life under review microscopy of immunohistochemically treated sections of thyroid glands of animals of intact and control groups using Fox-1 antibodies, it should be noted that the detection of Fox-1 expression was uniform over the entire area and in the experimental group in flattened thyrocytes of overstretched follicles, Fox-1 expression was present only in the apical part. Due to the mosaic location of follicles with flattened thyroid epithelium throughout the parenchyma of the gland, examination microscopy revealed the location of follicles with reduced Fox-1 expressive activity, indicating a decrease in synthetic organelles in such cells and reorganization of hormone-forming processes about disturbance of resorption function of thyrocytes.

At the period of 90–120th days in thyrocytes, regardless of the size of the follicles and location in the particle (peripheral or central part) throughout the parenchyma of the organ, a bright cytoplasmic reaction with Fox-1 antibodies was observed. Immunohistochemically Fox-1-positive cyto-

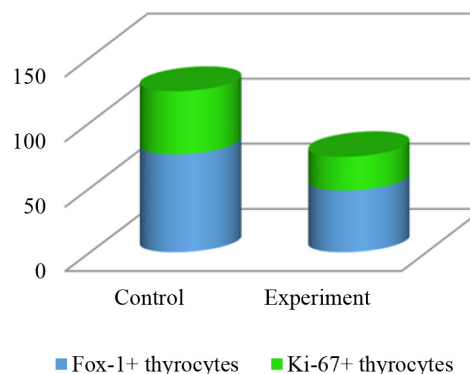
plasmic expression in most thyrocytes was present throughout the cytoplasm, occasionally in the apical part of thyrocytes, which indicated the intensive rapid development of the protein-synthesizing apparatus. The pattern of distribution of immunohistochemical Fox-1-positive reaction in thyrocytes of thyroid follicles of control and intact groups was mosaic and was visualized mainly in thyrocytes of peripheral follicles, and there was both nuclear and cytoplasmic positive reaction with Fox-1. Comparing the results of immunohistochemical studies with Fox-1 antibodies between groups, it should be noted that prenatal administration of dexamethasone affects about differentiation not only of structural and functional units – follicles, but also a specific synthetic intracellular apparatus of thyrocytes, which encode thyroglobulin synthesis, bind precisely due to Fox-1. Thus, immature pre-mRNA is converted into mature mRNA, from which thyroid proteins, in particular thyroglobulin, are translated [10]. At this age, there is a large number of light thyrocytes in the wall of the follicles, it is Ki-67-positive cell. The axis of proliferation is oriented parallel to the basement membrane of the follicle. If in the preparations of the thyroid gland of intact animals it was easy to find epithelial proliferative cell clusters, then in the glands of this period the animals of the experimental group they were almost absent (*fig. 2, a*). On the premarital period of life in the thyroid glands of animals in the experimental group thyrocytes high was 4.37 (3.35; 5.92) μm , which was 1.4 times

less than the control value. In the thyroid glands of animals after 90th day of the postnatal period, morphological changes occurred in all groups of the experiment (fig. 2, b).



a

a functional compensatory response of synthetic and hormone-producing function, but suppression of proliferative processes, despite the slight manifestations. Morphogenesis of the thyroid



b

Fig. 2. Histological structure and cytological profile of proliferative processes in the juvenile rat's thyroid gland: a – immunohistochemical study with Fox-1 antibodies non-positive reaction in thyrocytes of large size follicles, magnification $\times 400$; b – cytological profile of Fox-1 and Ki-67-positive thyrocytes in control group and experimentally prenatally exposed animals with dexamethasone, which reflects intracellular and cellular proliferative processes in the thyroid gland

Thus, in animals of the experimental group, which were prenatally exposed to dexamethasone, hollow follicles of colloidal type of large, medium and some small diameter were randomly visualized throughout the body, and large follicles of irregular shape with immunohistochemical weak or negative reaction with Fox-1 antibodies, which indicated a decrease in specific synthetic activity in these thyrocytes (fig. 2, a). Follicles filled with colloid with mosaic cytoplasmic and nuclear expression of Fox-1 antibodies in thyrocytes were present in the thyroid glands of animals of the control and intact groups. In most of the follicles of the peripheral part of the thyroid gland in thyrocytes there was a bright cytoplasmic reaction with Fox-1 antibodies.

Conclusions

Morphological signs of functional tension of the thyroid gland infantile animals exposed prenatally to dexamethasone, which correlate with a decrease in proliferative activity, indicate

gland by hypofunctional type after prenatal action of dexamethasone in young rats, indicates an adaptogenic compensatory response and morphofunctional immaturity of the organ during this period, which may be the basis for provoking the preservation of such morphogenetic factors under the influence of stressors. In rats prenatally receiving dexamethasone, this period was characterized by intense structural changes in the thyroid gland, in particular intracellularly in thyrocytes of monolayer flattened epithelium, the expression of Fox-1 antibodies was sharply reduced, which was then replaced by bright cytoplasmic and follicles of colloidal type of secretion, which is an adaptive-compensatory mechanism of intracellular enhancement of proliferation of synthesizing organelles in response to the rearrangement of a significant number of existing follicles by hypofunctional type, aimed at maintaining a normal level of thyroid function.

Список літератури

1. Аналіз поширеності тиреоїдної патології та захворюваності на неї серед населення Київської області та України за 2007–2017 рр. / В. І. Ткаченко, Я. А. Максимець, Н. В. Видиборець, О. Ф. Коваленко // Міжнародний ендокринологічний журнал. – 2018. – Т. 14, № 3. – С. 279–284.
2. Чукур О. О. Динаміка захворюваності й поширеності патології щитоподібної залози серед дорослого населення України / О. О. Чукур // Вісник соціальної гігієни та організації охорони здоров'я України. – 2018. – № 4 (78). – С. 19–25.

3. Effects of antenatal dexamethasone administration on fetal and uteroplacental Doppler waveforms in women at risk for spontaneous preterm birth / E. Elsnosy, O. M. Shaaban, A. M. Abbas [et al.] // *Middle East Fertility Society Journal*. – 2017. – Vol. 22, issue 1. – P. 13–17.
4. Antenatal corticosteroid treatment: factors other than lung maturation / K. Haram, J. H. Mortensen, E. F. Magann, J. C. Morrison // *The Journal of Maternal-Fetal & Neonatal Medicine*. – 2017. – Vol. 30, issue 12. – P. 1437–1441.
5. *Moisiadis V. G.* Glucocorticoids and fetal programming part 1: outcomes / V. G. Moisiadis, S. G. Matthews // *Nat. Rev. Endocrinol.* – 2014. – Vol. 10, issue 7. – P. 391–402.
6. *Rizzo L. F.* Drug-induced hypothyroidism / L. F. Rizzo, D. L. Mana, H. A. Serra // *Medicina (B Aires)*. – 2017. – Vol. 77, № 5. – P. 394–404.
7. *Ahmed R. G.* Gestational dexamethasone alters fetal neuroendocrine axis / R. G. Ahmed // *Toxicology Letters*. – 2016. – Vol. 258. – P. 46–54.
8. *Махинько В. И.* Константы роста и функциональные периоды развития в постнатальной жизни белых крыс / В. И. Махинько, В. Н. Никитин // *Молекулярные и физиологические механизмы возрастного развития*. – К. : Наукова думка, 1975. – С. 308–325.
9. *Ahmed R. G.* Letter: gestational dexamethasone may be at higher risk for thyroid disease developing peripartum / R. G. Ahmed // *Open Journal of Biomedical & Life Sciences*. – 2017. – Vol. 3, issue 2. – P. 01–06.
10. *Asztalos E.* Antenatal corticosteroids: a risk factor for the development of chronic disease / E. Asztalos // *J. Nutrition Metab.* – 2012. – Vol. 2012. – Article ID 930591.

References

1. Tkachenko V.I., Maksymets Ya.A., Vydyborets N.V., Kovalenko O.F. (2018). Analiz poshyrenosti tyreoidnoi patolohii ta zakhvoriuvanosti na nei sered naselennia Kyivskoi oblasti ta Ukrainy za 2007–2017 rr. [Analysis of the prevalence of thyroid pathology and its incidence among the population of Kyiv region and Ukraine for 2007–2017]. *Mizhnarodnyi endokrynolohichnyi zhurnal – International Journal of Endocrinology*, vol. 14, № 3, pp. 279–284. DOI: 10.22141/2224-0721.14.3.2018.136426 [in Ukrainian].
2. Chukur O.O. (2018). Dynamika zakhvoriuvanosti y poshyrenosti patolohii shchypodibnoi zalozy sered dorosloho naselennia Ukrainy [Dynamics of morbidity and prevalence of thyroid pathology among the adult population of Ukraine]. *Visnyk sotsialnoi hihiieny ta orhanizatsii okhorony zdorovia Ukrainy – Reports of Social Hygiene and Organization of Health Care of Ukraine*, № 4 (78), pp. 19–25. DOI: 10.11603/1681-2786.2018.4.10020 [in Ukrainian].
3. Elsnosy E., Shaaban O.M., Abbas A.M., Gaber H.H., Darwish A. (2017). Effects of antenatal dexamethasone administration on fetal and uteroplacental Doppler waveforms in women at risk for spontaneous preterm birth. *Middle East Fertility Society Journal*, vol. 22, issue 1, pp. 13–17. DOI: 10.1016/j.mefs.2016.09.007.
4. Haram K., Mortensen J.H., Magann E.F., Morrison J.C. (2017). Antenatal corticosteroid treatment: factors other than lung maturation. *The Journal of Maternal-Fetal & Neonatal Medicine*, vol. 30, issue 12, pp. 1437–1441. DOI: 10.1080/14767058.2016.1219716, PMID: 27487405.
5. Moisiadis V.G., Matthews S.G. (2014). Glucocorticoids and fetal programming part 1: outcomes. *Nat. Rev. Endocrinol.*, vol. 10, issue 7, pp. 391–402. DOI: 10.1038/nrendo.2014.73, PMID: 24863382.
6. Rizzo L.F., Mana D.L., Serra H.A. (2017). Drug-induced hypothyroidism. *Medicina (B Aires)*, vol. 77, № 5, pp. 394–404. PMID: 29044016.
7. Ahmed R.G. (2016). Gestational dexamethasone alters fetal neuroendocrine axis. *Toxicology Letters*, vol. 258, pp. 46–54. DOI: 10.1016/j.toxlet.2016.05.020, PMID: 27220267.
8. Mahinko V.I., Nikitin V.N. (1975). Konstanty rosta i funktsionalnyie periody razvitiia v postnatalnoi zhizni belykh kryss [Growth constants and functional periods of development in the postnatal life of white rats]. *Molekuliarnyie i fiziologicheskiie mehanizmy vozrastnoho razvitiia – Molecular and Physiological Mechanisms of Age-Related Development*. Kyiv: Naukova dumka, pp. 308–325 [in Russian].
9. Ahmed R.G. (2017). Letter: gestational dexamethasone may be at higher risk for thyroid disease developing peripartum. *Open Journal of Biomedical & Life Sciences*, vol. 3, issue 2, pp. 01–06.
10. Asztalos E. (2012). Antenatal corticosteroids: a risk factor for the development of chronic disease. *J. Nutrition Metab.*, vol. 2012, article ID 930591. DOI: 10.1155/2012/930591, PMID: 22523677, PMCID: PMC3317130.

О.В. Федосеева

ОСОБЕННОСТИ ПРОЛИФЕРАТИВНЫХ ПРОЦЕССОВ В ЩИТОВИДНОЙ ЖЕЛЕЗЕ ПОТОМКОВ КРЫС ЛИНИИ ВИСТАР ПОСЛЕ ВНУТРИУТРОБНОГО ВОЗДЕЙСТВИЯ ДЕКСАМЕТАЗОНА

Изучены особенности пролиферативных процессов в щитовидной железе потомков крыс линии Вистар после внутриутробного действия дексаметазона. Животные были разделены на три группы: I – интактные крысы; II – контроль – животные, которым на 18-е сутки беременности чрескожно, трансдермально, подкожно в межлопаточную область вводили 0,9 % физиологический раствор в количестве 0,05 мл; III – основная группа – животные, которым при лапаротомии внутриматочно, чрескожно подкожно в межлопаточную область вводили раствор дексаметазона в дозе 0,05 мл в разведении 1:40 на 18-й день беременности (патент Украины № 112288). Установлено, что щитовидная железа крыс инфантильного периода жизни, которые пренатально подверглись воздействию дексаметазона, структурно представлена хаотично расположенными фолликулами разного диаметра с превалированием крупных с десквамированными клетками в просвете и пролиферативными изменениями, направленными на формирование экстрафолликулярных скоплений с последующим формированием микрофолликулов, что подтверждено иммуногистохимически наличием Ki-67-положительных клеток. Внутриклеточно пролиферируют и белок-синтезирующие органеллы тироцитов, на что имеется яркая цитоплазматическая и ядерная реакция с Fox-1 антителами. В течение ювенильного периода пролиферативные процессы в щитовидной железе животных экспериментальной группы стабилизируются с сохранением морфологического строения по гипофункциональному типу и остаются ниже, чем у животных из группы контроля и интактных.

Ключевые слова: щитовидная железа, пролиферация, дексаметазон, эксперимент, крысы.

О.В. Федосеева

ОСОБЛИВОСТІ ПРОЛІФЕРАТИВНИХ ПРОЦЕСІВ У ЩИТОПОДІБНІЙ ЗАЛОЗІ НАЩАДКІВ ЩУРІВ ЛІНІЇ ВІСТАР ПІСЛЯ ВНУТРІШНЬОУТРОБНОГО ВПЛИВУ ДЕКСАМЕТАЗОНУ

Вивчено особливості проліферативних процесів у щитоподібній залозі нащадків щурів лінії Вистар після внутрішньоутробної дії дексаметазону. Тварин було розподілено на три групи: I – інтактні щури; II – контроль – тварини, яким на 18-ту добу вагітності черезшкірно, трансдермально, підшкірно в міжлопаткову ділянку вводили 0,9 % фізіологічний розчин у кількості 0,05 мл; III – основна група – тварини, яким при лапаротомії внутрішньоматково, черезшкірно підшкірно в міжлопаткову ділянку вводили розчин дексаметазону в дозі 0,05 мл у розведенні 1:40 на 18-й день вагітності (патент України № 112288). Установлено, що щитоподібна залоза щурів інфантильного періоду життя, які пренатально зазнали дії дексаметазону, структурно представлена хаотично розташованими фолікулами різного діаметра з превалюванням великих із десквамованими клітинами у просвіті та проліферативними змінами, направленими на формування екстрафолікулярних скупчень із подальшим формуванням мікрофолікулів, що підтверджено імуногістохімічно наявністю Ki-67-позитивних клітин. Внутрішньоклітинно проліферують і білок-синтезуючі органели тироцитів, на що є наявна яскрава цитоплазматична і ядерна реакції з Fox-1 антитілами. Протягом ювенільного періоду проліферативні процеси в щитоподібній залозі тварин експериментальної групи стабілізуються зі збереженням морфологічної будови за гіпофункціональним типом та залишаються нижчими, ніж у тварин із групи контролю та інтактних.

Ключові слова: щитоподібна залоза, проліферация, дексаметазон, експеримент, щури.

Надійшла 14.12.20

Відомості про автора

Федосеева Ольга Віталіївна – кандидат медичних наук, доцент кафедри гістології, цитології та ембріології Запорізького державного медичного університету.

Адреса: Україна, 69035, м. Запоріжжя, пр. Маяковського, 26, Запорізький державний медичний університет.

Тел.: +38(050)070-11-07; +38(067)355-77-45.

E-mail: fedoseeva.ov.1@gmail.com.

ORCID: <https://orcid.org/0000-0003-2247-1965>.