



# Study of the effect of sodium 2-((4-amino-5-(thiophen-2-ylmethyl)-4H-1,2,4-triazole-3-yl)thio)acetate toxic doses on rats heart tissue

A. A. Safonov<sup>1</sup>, O. I. Panasenko<sup>2</sup>, N. A. Al Khalaf<sup>3</sup>

Zaporizhzhia State Medical and Pharmaceutical University, Ukraine

A – research concept and design; B – collection and/or assembly of data; C – data analysis and interpretation; D – writing the article; E – critical revision of the article; F – final approval of the article

Analysis of medicinal product safety is an important stage on the way to the entry of a synthetic compound into the pharmaceutical market. Along with the study of blood composition, scientists are actively analyzing the effect of toxic doses on the tissues of internal organs. Analyzing the toxic effect of compounds on heart tissue allows us to find out what damage substances can cause, which can have a direct impact on human health. Today, 1,2,4-triazole derivatives are very relevant and a huge number of publications is a confirmation of this.

**The aim of the work** was to analyze the effect of toxic doses of sodium 2-((4-amino-5-(thiophen-2-ylmethyl)-4H-1,2,4-triazole-3-yl)thio)acetate on rats heart tissue.

**Materials and methods.** Sodium 2-((4-amino-5-(thiophen-2-ylmethyl)-4H-1,2,4-triazole-3-yl)thio)acetate (ASP) was selected as the subject of investigation and administered intragastrically in the form of a suspension with purified water using a specialized metal probe. The toxic effect on tissues was analyzed using doses of 1000 mg/kg, which is 10 times higher than a single dose typically used in pharmacological activity studies, and 5000 mg/kg, which represents the limit for determining acute toxicity and the maximum dose within the fourth class of toxicity, considering the route of administration, provided that this dose does not result in the death of the animal.

Analysis of the effect of toxic doses of ASP was performed on 12-month-old purebred male rats kept under standard conditions. Rat heart tissues were fixed for further histological examination in a 10 % formaldehyde solution, dehydrated in alcohols of increasing strength, and embedded in paraffin.

**Results.** Macroscopic and microscopic analysis of rat heart tissue was carried out. The research shows the histological results of deviations from the norm for a group of rats that were injected with substances in the studied doses.

**Conclusions.** The effect of toxic doses of ASP on rat heart tissue was analyzed. For a dose of 1000 mg/kg, local signs of protein dystrophy of cardiomyocytes and single loci of hemorrhages are observed. As for the dose of 5000 mg/kg, the effect of the substance on the heart tissue is more profound and is determined by the selective damage of cardiomyocytes with the loss of lumbar striation and the acquisition of a wave-like shape, full blood is observed in the ectasized capillaries.

**Keywords:** 1,2,4-triazole, rats, heart tissue, toxic action.

**Current issues in pharmacy and medicine: science and practice. 2024;17(2):150-153**

## Дослідження впливу токсичних доз 2-((4-аміно-5-(тіофен-2-ілметил)-4H-1,2,4-тріазол-3-іл)тіо)ацетату на тканину серця щурів

A. A. Сафонов, О. І. Панасенко, Н. А. Аль Халаф

Аналіз безпечності лікарського засобу є важливим етапом на шляху синтетичної сполуки до фармацевтичного ринку. Разом із дослідженням складу крові, вчені активно аналізують вплив токсичних доз на тканини внутрішніх органів. Аналіз токсичного впливу сполук на тканини серця дає змогу з'ясувати, які пошкодження можуть викликати речовини, опосередковано впливаючи на здоров'я людини. Нині похідні 1,2,4-тріазолу залишаються актуальним об'єктом дослідження, що підтверджено величезною кількістю публікацій.

**Мета роботи** – аналіз впливу токсичних доз 2-((4-аміно-5-(тіофен-2-ілметил)-4H-1,2,4-тріазол-3-іл)тіо)ацетату на тканини серця щурів.

**Матеріали і методи.** Як об'єкт дослідження використано 2-((4-аміно-5-(тіофен-2-ілметил)-4H-1,2,4-тріазол-3-іл)тіо)ацетат (ASP), який вводили внутрішньошлунково у формі суспензії з очищеною водою за допомогою спеціального металевго зонда. Для аналізу токсичного впливу на тканини обрали дози 1000 мг/кг (це вдесятеро перевищує разову дозу, що рекомендована під час вивчення фармакологічної активності досліджуваної сполуки) та 5000 мг/кг (граничний показник для визначення гострої токсичності й максимальна доза четвертого класу токсичності, враховуючи шлях введення, якщо ця доза не призводить до смерті тварини).

### ARTICLE INFO



UDC 615.31.099:547.792'732:611.12.018]-092.9  
DOI: [10.14739/2409-2932.2024.2.300859](https://doi.org/10.14739/2409-2932.2024.2.300859)

**Current issues in pharmacy and medicine: science and practice. 2024;17(2):150-153**

**Keywords:** 1,2,4-triazole, rats, heart tissue, toxic action.

\*E-mail: [8safonov@gmail.com](mailto:8safonov@gmail.com)

Received: 11.03.2024 // Revised: 28.03.2024 // Accepted: 05.04.2024

Дію токсичних доз ASP досліджували на білих безпородних щурах-самцях віком 12 місяців, яких утримували за стандартних умов. Тканини серця щурів для гістологічного дослідження фіксували в 10 % розчині формальдегіду, зневоднювали у спиртах висхідної концентрації, заливали парафіном.

**Результати.** Здійснили макроскопічний і мікроскопічний аналіз тканини серця щурів. У дослідженні наведено гістологічні результати відхилень від норми для групи щурів, яким вводили речовину в дозах, що вивчали.

**Висновки.** Проаналізовано вплив токсичних доз ASP на тканини серця щурів. Встановили, що доза ASP 1000 мг/кг спричиняє локальні ознаки білкової дистрофії кардіоміоцитів й одиничні локуси крововиливів. У разі введення ASP у дозі 5000 мг/кг вплив речовини на тканину серця істотніший, визначається селективним пошкодженням кардіоміоцитів із втратою поперекової смугастості та набуттям хвилеподібної форми, виявили повнокров'я в ектазованих капілярах.

**Ключові слова:** 1,2,4-тріазол, тканина серця щурів, токсична дія.

**Актуальні питання фармацевтичної і медичної науки та практики.** 2024. Т. 17, № 2(45). С.150-153

According to statistics from the World Health Organization, cardiovascular diseases have been the leading cause of death for over 20 years. The heart is one of the main life-sustaining organs of a person. Along with other organs, the heart is a “target organ” and, therefore, is mandatory for research [1]. Analyzing the toxic effect of compounds on heart tissue allows us to find out what damage substances can cause, which can have a direct impact on human health.

1,2,4-Triazole derivatives can be chosen among the new substances that can become medicines in the future. Today, they are very relevant and a huge number of publications is a confirmation of that [2,3,4,5,6,7,8,9]. Scientists from all over the world are working on the development of substances [10,11,12,13,14].

Analysis of the safety of a medicinal product is an important stage on the way to the entry of a synthetic compound into the pharmaceutical market [15]. Along with the study of blood composition, scientists are actively analyzing the effect of toxic doses on the internal organs tissues.

## Aim

Thus, the aim of the study is to analyze the effect of toxic doses of sodium 2-((4-amino-5-(thiophen-2-ylmethyl)-4H-1,2,4-triazole-3-yl)thio)acetate on rats heart tissue.

## Material and methods

Sodium 2-((4-amino-5-(thiophen-2-ylmethyl)-4H-1,2,4-triazole-3-yl)thio)acetate (ASP) [16] was used as the object of study and administered intragastrically in the form of a suspension with purified water using a special metal probe. It was chosen for doses of 1000 and 5000 mg/kg (the limiting indicator for determining acute toxicity is the maximum dose of the fourth class of toxicity (low-toxic substances), taking into account the route of administration).

Analysis of the effect of ASP toxic doses was performed on white outbred male rats aged 12 months, which were kept in standard conditions [17]. All stages of the study were conducted by the Directive of the European Parliament and of the Council 2010/63/EU of 22 September 2010 “On the protection of animals used for scientific purposes” (Approval of the ethics committee No. 5 of 05.09.2023) [18].

The rats heart tissue was fixed for further histological examination in 10 % formaldehyde solution, dehydrated in

alcohols of increasing strength, poured into paraffin. Analysis of micropreparations was performed under a Granum light microscope.

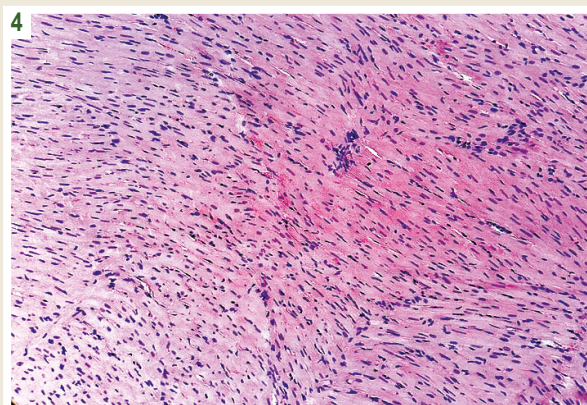
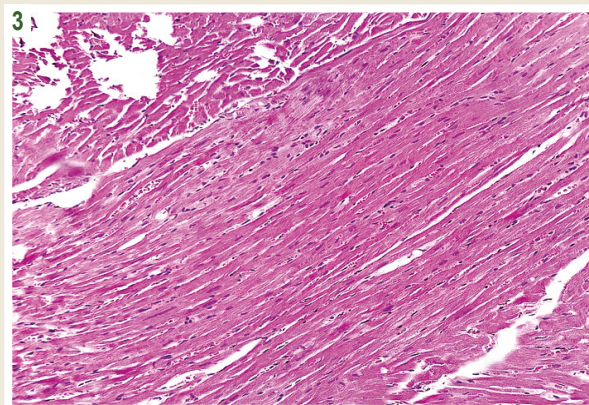
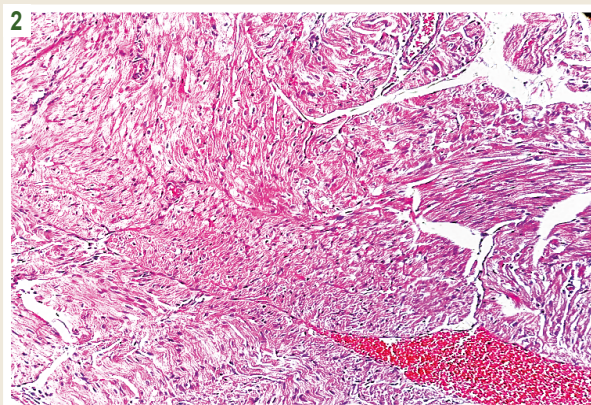
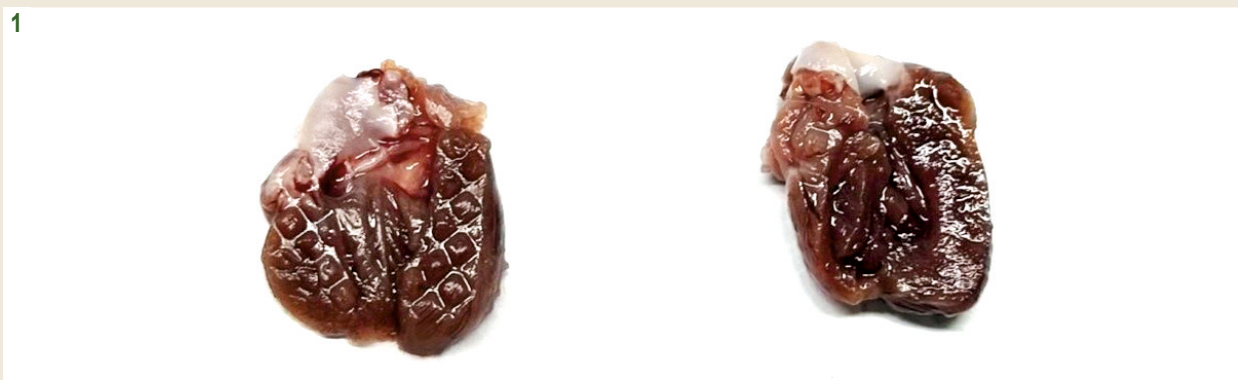## Results

At the beginning of the study, the heart of the studied group of animals was weighed, the weight of which was 0.9–1.1 g. For the control group, it was 1.0–1.1 g. Macroscopically, for both groups of animals, the heart was red-purple, densely elastic, coronary vessels full-blooded, with a clear visual course. When the incision is made in the cavities of the ventricles, blood is detected, the walls of the myocardium are red without macroscopic pathology. The atrium is visually without dilatation, a typical configuration (Fig. 1).

With a more detailed microscopic analysis of the experimental group (1000 mg/kg) of rats, the following was found: zones of disorganization of cardiomyocytes with preservation of the lumbar striation of myofibrils are identified in the myocardium, the cytoplasm of many cells is eosinophilic, deep. Individual loci of subendocardial hemorrhages are determined. The symplastic structure is not preserved, local signs of protein dystrophy of cardiomyocytes, the fine capillary net is ectasized (Fig. 2).

A pathomorphological study of rats' hearts (the group – 5000 mg/kg) was also carried out. The histological structure of the myocardium is disturbed due to the disorganization of cardiomyocytes, which acquire a wave-like structure, the zones of cardiomyocytes with the loss of the lumbar striation of myofibrils are determined, the cytoplasm is eosinophilic, deep, homogeneous in places. The symplastic structure is disturbed, nuclei in a state of karyopyknosis and karyolysis are determined in individual cardiomyocytes. Histological manifestations of intercellular edema, small capillary net ectasized, full-blooded, zones of erythrodiapiesis (Fig. 3).

Studying heart tissues of the control group revealed: cardiomyocytes of typical sizes. It should be noted that the transverse striation and symplastic structure are preserved in all cells, the nuclei are typical sizes, oval in shape, basophilic have 1–2 nucleoli (Fig. 4). Pacemaker cells of the conducting system of the heart have typical histological structure, rounded shape, with light oxyphilic cytoplasm and a centered nucleus. The capillary net of the myocardium has collapsed, endotheliocytes have a typical histological structure, and single erythrocytes are identified in the lumen. The endocardium has a typical his-



**Fig. 1.** Projection of the left ventricle of the studied heart (left). Projection of the left ventricle of the control group animal heart (right).

**Fig. 2.** Protein and vacuolar dystrophy of cardiomyocytes, areas of hemorrhage. Magnified  $\times 200$ . Stained with hematoxylin and eosin.

**Fig. 3.** Selective damage to cardiomyocytes with loss of lumbar striation and acquisition of wave-like form of whole blood in ectasized capillaries. Magnified  $\times 200$ . Stained with hematoxylin and eosin.

**Fig. 4.** Histological photo of rat myocardium (control group). Magnified  $\times 200$ . Stained with hematoxylin and eosin.

tological structure, consisting of one layer of endotheliocytes, single connective tissue fibers are determined along the course of cardiomyocytes and around large main vessels.

### Discussion

It should be noted that the studied substance ASP affects heart tissue if the data is compared with the control group of rats. It was also established that at a dose of 5000 mg/kg, there

is a loss of lumbar striated myofibrils. In the control group, transverse striation and symplastic structure were preserved in all cells. But, despite this, all the functions of the heart muscle are preserved.

Summarizing the obtained data, it can be concluded that in high doses, the substance begins to have a toxic effect on the heart tissues, and with an increase in the dose, the damage is greater, which is natural. But these damages do not lead to the death of the animal.

## Conclusions

1. The effect of toxic doses (1000 mg/kg, 5000 mg/kg) of sodium 2-((4-amino-5-(thiophen-2-ylmethyl)-4H-1,2,4-triazole-3-yl)thio)acetate on rat heart tissue was analyzed.

2. For a dose of 1000 mg/kg, local signs of protein dystrophy of cardiomyocytes and single loci of hemorrhages are observed.

3. As for the maximum dose of the fourth class of toxicity (5000 mg/kg), the effect of the substance on the heart tissue is more profound and is determined by the selective damage of cardiomyocytes with the loss of lumbar striation and the acquisition of a wave-like shape, full blood is observed in the ectasized capillaries.

**Conflicts of interest:** authors have no conflict of interest to declare.

**Конфлікт інтересів:** відсутній.

### Information about the authors:

Safonov A. A., PhD, Associate Professor of the Department of Toxicological and Inorganic Chemistry, Zaporizhzhia State Medical and Pharmaceutical University, Ukraine.

ORCID ID: 0000-0003-2861-1826

Panasenko O. I., PhD, DSc, Professor, Head of the Department of Toxicological and Inorganic Chemistry, Zaporizhzhia State Medical and Pharmaceutical University, Ukraine.

ORCID ID: 0000-0002-6102-3455

Al Khalaf N. A., PhD, Senior Lecturer of the Department of Toxicological and Inorganic Chemistry, Zaporizhzhia State Medical and Pharmaceutical University, Ukraine.

ORCID ID: 0000-0002-2915-6055

### Відомості про авторів:

Сафонов А. А., канд. фарм. наук, доцент каф. токсикологічної та неорганічної хімії, Запорізький державний медико-фармацевтичний університет, Україна.

Панасенко О. І., д-р фарм. наук, професор, зав. каф. токсикологічної та неорганічної хімії, Запорізький державний медико-фармацевтичний університет, Україна.

Аль Халаф Н. А., канд. фарм. наук, старший викладач каф. токсикологічної та неорганічної хімії, Запорізький державний медико-фармацевтичний університет, Україна.

## References

- Gupta PK. Target Organ Toxicity. In: Problem Solving Questions in Toxicology: Cham: Springer International Publishing; 2020. p. 83-117. doi: 10.1007/978-3-030-50409-0
- Sameliuk Y, Al Zedan F, Kaplaushenko T. 1,2,4-triazole derivatives in medicine and pharmacy and application prospects. Journal of Faculty of Pharmacy of Ankara University. 2021;45(3):598-614. doi: 10.33483/jfpau.885888
- Shcherbyna R. Microwave-assisted synthesis of some new derivatives of 4-substituted-3-(morpholinomethyl)-4H-1,2,4-triazole-5-thioles. Journal of Faculty of Pharmacy of Ankara University. 2019;43(3):220-9. doi: 10.33483/jfpau.533166
- Safonov A. Microwave synthesis of new N-R-3-(alkylthio)-5-(thiophen-2-ylmethyl)-1,2,4-triazol-4-amines. Journal of Faculty of Pharmacy of Ankara University. 2020;44(1):89-98. doi: 10.33483/jfpau.620599
- Dovbnia D, Frolova Y, Kaplaushenko A. A study of hypoglycemic activity of acids and salts containing 1,2,4-triazole. Ceska Slov Farm. 2023;72(3):113-24.
- Sameliuk Y, Kaplaushenko A, Nedorezaniuk N, Ostretsova L, Diakova F, Gutyj B. Prospects for the search for new biologically active compounds among the derivatives of the heterocyclic system of 1, 2, 4-triazole. Hacettepe University Journal of the Faculty of Pharmacy. 2022;42(3):175-86. doi: 10.52794/hujpharm.1019625
- Shcherbyna R, Parchenko V, Varynskyi B, Kaplaushenko A. The development of HPLC-DAD method for determination of active pharmaceu-
- Frolova Y, Kaplaushenko A, Nagornaya N. Design, synthesis, antimicrobial and antifungal activities of new 1,2,4-triazole derivatives containing 1H-tetrazole moiety. Journal of Faculty of Pharmacy of Ankara University. 2020;44(1):70-88. doi: 10.33483/jfpau.574001
- Shcherbyna R. An investigation of the pharmacokinetics and potential metabolites of potassium 2-((4-amino-5-(morpholinomethyl)-4H-1,2,4-triazol-3-yl)thio) acetate on rats. Journal of Faculty of Pharmacy of Ankara University. 2020;44(2):233-41. doi: 10.33483/jfpau.681611
- Shcherbyna R, Vashchuk Y. The research of 1,2,4-triazole derivatives hepatoprotective activity under tetracycline and infectious hepatitis. Journal of Faculty of Pharmacy of Ankara University. 2019;43(2):135-46. doi: 10.33483/jfpau.487173
- Gotsulya A. Synthesis and antiradical activity of alkyl derivatives of 5-(5-methyl-1H-pyrazol-3-yl)-4-phenyl-4H-1,2,4-triazole-3-thiol. Journal of Faculty of Pharmacy of Ankara University. 2020;44(2):211-9. doi: 10.33483/jfpau.616116
- Gotsulya A, Zaika Y, Brytanova T. Synthesis, properties and biological potential some condensed derivatives 1,2,4-triazole. Journal of Faculty of Pharmacy of Ankara University. 2022;46(2):308-21. doi: 10.33483/jfpau.971602
- Sameliuk Y, Kaplaushenko A. Synthesis of 3-alkylthio(sulfo)-1,2,4-triazoles, Containing methoxyphenyl substituents at c5atoms, Their antipyretic activity, Propensity to adsorption and acute toxicity. Journal of Chemical and Pharmaceutical Research. 2014;6(5):1117-21.
- Safonov AA, Panasenko OI. Synthesis, antimicrobial and antifungal activity of 3-(2-bromophenyl)-5-(alkylthio)-4-phenyl-4H-1,2,4-triazoles. Current issues in pharmacy and medicine: science and practice. 2022;15(3):235-40. doi: 10.14739/2409-2932.2022.3.264691
- Bondarenko LB, Voronina A K, Shayakhmetova HM, Blazhchuk IS, Karatsuba TA, Kovalenko VM. [Study of essential phospholipids preparation subacute toxicity]. Farmakolohiia ta likarska toksykolohiia. 2022;16(4):248-63. Ukrainian. doi: 10.33250/16.04.248
- Knysh Y, Panasenko O, Safonov A, inventors. [Sodium 2-((4-amino-5-(thiophen-2-ylmethyl)-4H-1,2,4-triazol-3-yl)thio)acetate, which shows actoprotective activity]. Ukrainian patent UA 112619. 2016 Sep 26. Available from: <https://sis.nipo.gov.ua/en/search/detail/455441/>
- Guide for the Care and Use of Laboratory Animals [Internet]. Washington, D. C.: National Academies Press; 2011. Available from: <https://www.ncbi.nlm.nih.gov/books/NBK54050/>
- European Union. Directive 2010/63/EU of the European Parliament and of the Council of 22 September 2010 on the protection of animals used for scientific purposes. Official Journal of the European Union, L276/33, 2010.