



M. L. Golovakha, M. A. Kozhemyaka, S. O. Maslennikov

Evaluation of the results of surgical treatment of ankle fractures with the tibiofibular syndesmosis injury

Zaporizhzhia State Medical University, Ukraine

Key words: *Ankle Fractures, Tibiofibular Syndesmosis, Orthopedic Procedures, Surgical Traumatology.*

Background. Ankle fractures are the most common injuries among the damages of ankle joint. The most common complication in such fractures is the damage of the tibiofibular joint, leading to increase in the duration of treatment and adverse outcomes. Despite the large number of publications, the problem of this type injury treatment is far from solving it. The questions remain open regarding the method of surgical treatment and results evaluation.

Aim. To evaluate the results of surgical treatment of ankle fractures, complicated with tibiofibular syndesmosis injury with the help of hardware-bazometric complex and make a comparison with the existing methods of assessment, such as AOFAS and OMAS.

Materials and methods. This study presents an analysis of 80 patients with mentioned fractures surgical treatment results. Patients were divided into 2 groups. The first group (44 patients) was treated with the help of tension band wiring for fixing tibiofibular syndesmosis in combination with the original extramedullary plate with polyaxial insertion and blocking of screw for osteosynthesis of lateral malleolus fractures. The second group (36 patients) was treated according to the AO technique. The analysis of results was performed in 3, 6 and 12 months after surgery use of scales AOFAS and OMAS, as well as bazometric and stabilometric assessment using "Bazometr" complex.

Results. In 3 and 6 months AOFAS and OMAS results corresponded to data of bazometric and stabilometric indicators. The analysis showed the best results among the first group of patients, especially in the early stages. In 12 months the difference between indicators reduced, but remained significantly better in the 1st group.

Conclusions. The reported data of clinical observations and their analysis demonstrate the effectiveness of the proposed method of ankle fractures with the tibiofibular syndesmosis injury surgical treatment.

Zaporozhye medical journal 2016; №6 (99): 72–76

Оцінювання результатів хірургічного лікування переломів кісточок, що ускладнені пошкодженням міжгомількового синдесмозу

М. Л. Головаха, М. О. Кожем'яка, С. О. Масленніков

Переломи кісточок належать до ушкоджень гомількостопного суглоба, що трапляються найчастіше. Пошкодження міжгомількового зчленування під час переломів кісточок є доволі частим ускладненням, що призводить до збільшення термінів лікування та несприятливих результатів. Незважаючи на велику кількість публікацій, проблема лікування цього виду травм далека від її вирішення. Актуальними залишаються питання вибору лікувальної тактики, способу хірургічного лікування та оцінювання результатів.

Мета роботи – оцінювання результатів хірургічного лікування переломів кісточок, що ускладнені пошкодженням міжгомількового синдесмозу, за допомогою програмно-апаратного комплексу «Базометр» і загальноприйнятих методів оцінювання, таких як шкали AOFAS (American Orthopaedic Foot and Ankle Society) і OMAS (Olerud-Molander Analogue Scale).

Матеріали та методи. Представлений аналіз результатів хірургічного лікування 80 пацієнтів із переломами кісточок, що ускладнені пошкодженням міжгомількового синдесмозу. Пацієнтів поділили на дві групи. У першій групі 44 пацієнтам здійснили лікування з використанням напруженої петлі для фіксації міжгомількового синдесмозу в комбінації з оригінальною накістковою пластиною з можливістю поліаксіального введення та блокування гвинтів для остеосинтезу переломів латеральної кісточки. У другій групі 36 пацієнтів лікували згідно з технікою AO (Arbeitsgemeinschaft für Osteosynthesefragen). Здійснили аналіз результатів на 3, 6 і 12 місяць після операції з використанням шкал AOFAS та OMAS, а також базометричне та стабілометричне оцінювання з використанням програмно-апаратного комплексу «Базометр».

Результати. На 3, 6 і 12 місяць результати оцінювання за шкалами AOFAS та OMAS відповідають даним базометричного та стабілометричного оцінювання. Аналіз продемонстрував кращі показники в пацієнтів першої групи, особливо в ранніх термінах. До 12 місяців різниця показників зменшувалася, але зберігалась вірогідно краще в 1 групі.

Висновки. Дані клінічних спостережень та їхній аналіз демонструють ефективність запропонованого методу хірургічного лікування переломів кісточок, що ускладнені пошкодженням міжгомількового синдесмозу.

Ключові слова: *переломи кісток, міжгомільковий синдесмоз, ортопедичні процедури, хірургічна травматологія.*

Запорізький медичний журнал. – 2016. – №6 (99). – С. 72–76

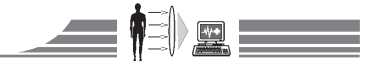Оценка результатов хирургического лечения переломов лодыжек, осложнённых повреждением межберцового синдесмоза

М. Л. Головаха, М. А. Кожемьяка, С. О. Масленников

Переломы лодыжек относятся к числу наиболее часто встречающихся поврежденных голеностопного сустава. Повреждение межберцового сочленения при переломах лодыжек является достаточно частым осложнением, приводящим к увеличению сроков лечения и неблагоприятным результатам. Несмотря на большое количество публикаций, проблема лечения данного вида травм далека от её решения. Актуальными остаются вопросы выбора лечебной тактики, способа хирургического лечения и оценки результатов.

Цель работы – оценка результатов хирургического лечения переломов лодыжек, осложнённых повреждением межберцового синдесмоза с помощью програмно-апаратного комплексу «Базометр» и общепринятых методов оценки, таких как шкалы AOFAS (American Orthopaedic Foot and Ankle Society) и OMAS (Olerud-Molander Analogue Scale).

Материалы и методы. В работе представлен анализ результатов хирургического лечения 80 пациентов с переломами лодыжек, осложнённых повреждением межберцового синдесмоза. Пациенты были разделены на две группы. В первой группе 44 пациентам



проведено лечение с использованием напряжённой петли для фиксации межберцового синдесмоза в комбинации с оригинальной наkostной пластиной с возможностью полиаксиального введения и блокирования винтов для остеосинтеза переломов латеральной лодыжки. Во второй группе 36 пациентам проведено лечения согласно технике АО (Arbeitsgemeinschaft für Osteosynthesefragen). Проведён анализ результатов в 3, 6 и 12 месяцев после операции с использованием шкал AOFAS и OMAS, а также базометрическая и стабиллометрическая оценка с использованием программно-аппаратного комплекса «Базометр».

Результаты. На 3, 6 и 12 месяцев результаты оценки по шкалам AOFAS и OMAS соответствуют данным базометрической и стабиллометрической оценки. Проведённый анализ продемонстрировал лучшие показатели у пациентов первой группы, особенно в ранних сроках. К 12 месяцам разница показателей уменьшалась, однако сохранялась достоверно лучше в 1 группе.

Выводы. Данные клинических наблюдений и их анализ демонстрируют эффективность предложенного метода хирургического лечения переломов лодыжек, осложнённых повреждением межберцового синдесмоза.

Ключевые слова: перелом костей, межберцовый синдесмоз, ортопедические процедуры, хирургическая травматология.

Запорожский медицинский журнал. – 2016. – №6 (99). – С. 72–76

The ankle injuries are one of the most frequent pathologies in daily medical practice of traumatology-orthopedist, the frequency of their damages amounts to 20% of all musculoskeletal system injuries. According to the literature, the occurrence rate of ankle fractures reaches 107–187 cases per 100 thousand of population per year [1,2]. It should be noted that 70% of the malleolar fractures are an isolated fractures of the one ankle [1,3]. The most common mechanism of injury, leading to fracture of the ankles, is supination mechanism, the second one by frequency – pronation mechanism [1,2]. Up to 30% of the malleolar fractures are accompanied by rupture of the distal tibiofibular syndesmosis [4]. Ankle fractures disability reaches 8.8–46% [5,6], and in trauma with rupture of the distal tibiofibular syndesmosis – 61%. At the same time about half of cases develop chronic ankle instability and rapid development of osteoarthritis. Both intra-articular and periarticular damages require accurate anatomical reposition and ensure the early functions in order to restore the full supporting ability of the limb. In Ukraine and abroad various methods for evaluating the degree of functional recovery after traumas are developed, and the search continues for organizational and technological methods to ensure guaranteed the high level of rehabilitation quality control. The evaluation systems are developed at present, largely subjective, designed for self-assessment by patients of private functions and tasks. At the core of research on the quality of care and rehabilitation should be based on standardized, evidence-based technology, objective methods of assessing the results of treatment.

The aim of the study

To evaluate the results of ankle fractures surgical treatment, complicated with tibiofibular syndesmosis injury with the help of hardware-bazometric complex and make a comparison with

the existing methods of assessment, such as AOFAS [7] and Olerud-Molander Analogue Scales (OMAS) [8].

Materials and methods

In order to study the structure and relationships of the post-operative stage of treatment major indicators in adult patients with ankle fractures with tibiofibular syndesmosis injury, the long-term effects of 80 adult patients' operative treatment were studied. Patients with ankle fractures with tibiofibular syndesmosis injury were divided into two groups: the 1st group – 44 patients whom an open fracture reposition of lateral ankle and subsequent fixation with the help of plates with the possibility of multi-axis insertion and blocking screws of the original design was performed. Fixation of tibiofibular syndesmosis was carried out with the help of tension band wiring [9–11] (Fig. 1).

Previously believed that the optimal position for the tension band wiring syndesmosis fixation is situated 2 cm above the ankle. The tension band wiring in this area performing by two loops to achieve the maximum possible angle between the loops and to provide the greatest stability of lateral ankle of fibula in tibial incisura fixation in both the sagittal and frontal planes. The 2nd group – 36 patients who were carried out surgery by the methodology of AO (Osteosynthesis of the lateral malleolus fractures with the help of extramedullary plate and the 3.5 mm position screw that holds the lateral ankle in the incisura of tibia).

In all groups in case of ankle fractures of the medial malleolus and/or posterior edge of the tibia an open reposition and fixation with screws or wires were performed, restoring damaged coherent structure of lateral and medial parts of joint.

A local compression hypothermia of operated segment was performed during the first postoperative day for all patients; intraoperative antibiotic therapy – intravenously infusion of

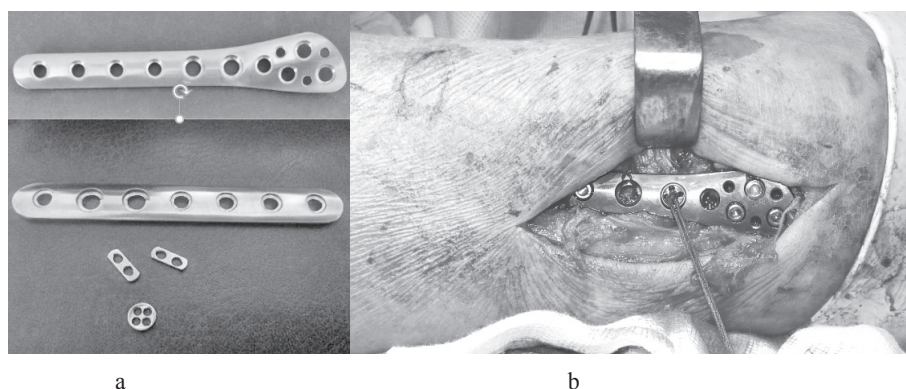
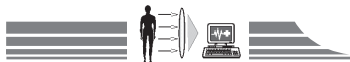

Fig. 1.

a – photo of original plates for osteosynthesis and metal elements for fixation of tension band wiring;

b – lateral ankle fracture fixation using plate with tibiofibular syndesmosis fixation with the help of tension band wiring.



2.0 grams of Cefazolin and then – intravenously infusion of 1.0 gram of Cefazolin 2 times a day for 72 hours after surgery. In all cases immobilization of operated joint was carried out with brace or posterior plaster splint in the first 24 hours after surgery to minimize swelling and degree of pain manifestation, and also for improving the healing of soft tissue. Patients after the tension band wiring fixation of syndesmosis in 4 weeks were allowed the axial load on the operated extremity in orthosis at the 50 % of normal level, full load after 8 weeks after surgery. Patients from the 2nd group were allowed of full axial load only after removing the positional screw in 8–10 weeks after surgery.

It was taking into account the gender and age, diagnosis, type of osteosynthesis, residual treatment defects at the time of discharge from hospital. Women dominated among the hospitalized, accounting for more than half the cases (24 cases – 55 % and 19 cases – 54 % respectively), male accounted in the first group 45 %, in the second – 46 % ($p < 0.05$). All surveyed patients were diagnosed with a broken ankle, complicated tibiofibular syndesmosis injury. The average age of the examined patients in the first group was 34.5 years, the second group – 38.1 ($p < 0.05$).

Evaluation of the results was carried out in 3, 6 and 12 months after surgery with the help of the AOFAS and Olerud-Molander scales. Subjective criteria assessed by the method of individual anonymous questionnaires. After 12 months patients were offered subjectively evaluate the result as excellent, good, satisfactory or poor. In addition, a control bazometric examination of the lower extremities supporting ability recovery with the help of hardware and software “Bazometr”, which was developed by the Ukrainian Research Institute of Prosthetics, Prosthesis and restore functionality, was performed. The main function of the basometer is to record parameters of patients’ reaction support basic vectors. The complex includes an IBM compatible personal computer, platform with two force measuring platforms, laser emitter module and software (Fig. 2). The complex allows evaluating the supporting ability and human resistance while saving vertical position by means of the stabilometric and bazometric methods.

Determination of the base vector position relative to the pa-

tient’s body allows correct identification of the load distribution between healthy and diseased lower extremities.

Determination of the base vector coordinates of the supporting reaction are provided by pads with force measuring elements, the computing device for processing the results of the individual force measuring elements and the unit display the received information in a convenient form for analysis.

In the static characteristics study of patients with ankle fractures with the tibiofibular syndesmosis rupture obtained parameters should be compared with the parameters of the conditional norms.

Support ratio (CPC) while standing on healthy feet is 1.0. In patients with ankle fracture with tibiofibular syndesmosis injury reference value of supports rate depends on the type of performed operative treatment and degree of fixation – the less stable fixation and the harder the pathology, the less the load on the injured extremity.

Angle of rotation, which reflects the diagonal warp of supports, in a healthy person is equal to 0.0 ± 0.2 deg. By increasing these values follows the increasing of diagonal skew support and pronounced poses asymmetry. A minus sign (-) before the value of the angle is put in the case if the offset of the pressure center forward of left lower extremity more than right one, a plus sign (+) – on the contrary.

Statistical and graphical processing of the obtained results was carried out by using package Microsoft Office Excel 2013 and Statistica 8.0 © StatSoft Inc. In processing the obtained results the methods of descriptive statistics have been used: calculation of mean values and standard deviation. Differences between average values considered reliable when p-value is less than or equal to the significance level 0.05 (Student’s t-test). For verifying the normality of the distribution the Selective asymmetry coefficient was used.

Results and discussion

In patients from the group with fixing of syndesmosis using tension band wiring the average values by the AOFAS scale were better than in patients whom a screw fixation of syndesmosis were performed (Table 1).

In patients from the group with fixing of syndesmosis using

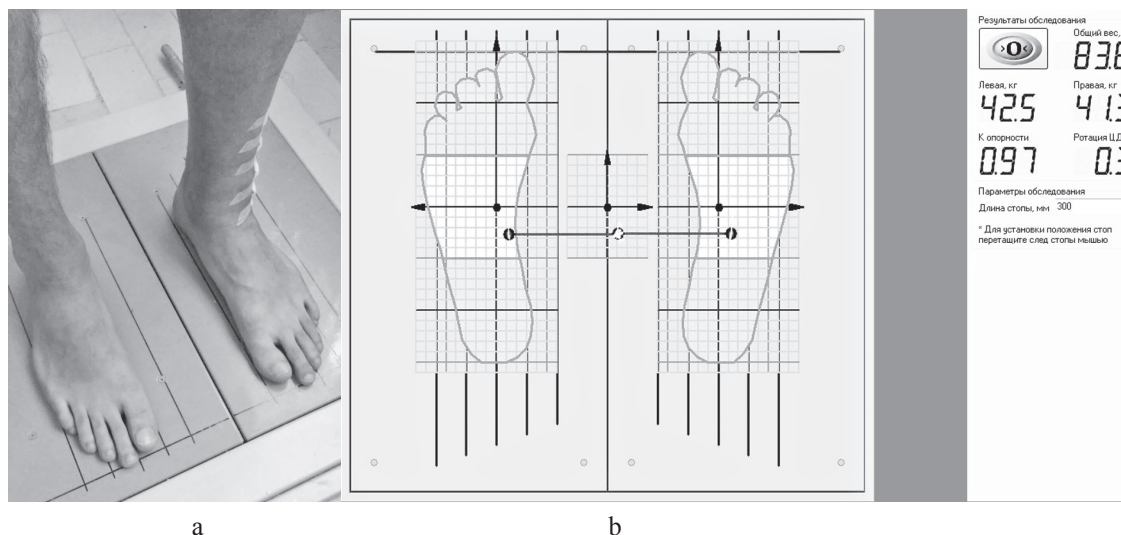


Fig. 2. Position of the patient on the platform (a) and protocol of bazometric exploration (b).



tension band wiring average values by the OMAS were better than in patients whom a screw fixation of syndesmosis were performed (Fig. 3).

The average value of the reference support's rate and the rotation centers of gravity were significantly better in the group with the fixation with the help of tension band wiring ($p \leq 0.05$) after 3 months and the following measurements after 6 and 12 months, albeit with a lesser difference of mean values (Table 2).

Average values of supporting ability of sore feet in the case of fixing with the help of tension band wiring remained reliably better than supporting ability of damaged legs in a group with the fixation by the AO method ($p \leq 0.05$) after 3, 6 and 12 months, although with somewhat less difference of averages values (Table 3).

In 3 and 6 months AOFAS and OMAS results approached to basometric indicators appropriate postoperative period in 3 and 6 months. After 12 months results of AOFAS and OMAS were completely similar and confirmed by basometric indicators.

According to the materials of the work we have performed an analysis of complications that occurred in patients of the selected category during observation period of 1 year. Among the 80 operated patients in both clinical groups 1 patient of the 1st group and 6 patients of the 2nd group developed complications, the structure of which is shown in the table (Table 4).

Table 1

Functional results of treatment by the AOFAS scale (max 100 points)

Observation terms	Operated with the help of tension band wiring, n=44	Operated by the AO method, n=36
3 months	82.2 points	68.4 points
6 months	91.3 points	86.1 points
12 months	98.4 points	91.7 points

Results of treatment according to the Olerud&Molander analogue scale

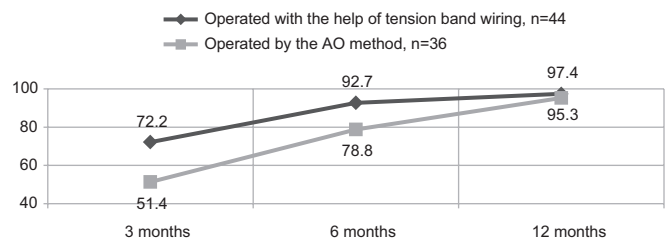


Fig. 3. Results of ankle fractures with the tibiofibular syndesmosis injury treatment according to the C. Olerud&H. Molander linear analogue scale (in % respectively to "absolutely healthy joint").

Table 2

Results of treatment of fractures by fixing with the help of tension band wiring and AO technique according to data of bazometric research

Observation terms	Operated with the help of tension band wiring, n=44		Operated by the AO method, n=36	
	Support ratio	Rotation of pressure centres, grad.	Support ratio	Rotation of pressure centres, grad.
3 months	0.65±0.04 cu	1.2±0.1 grad	0.5±0.03 cu	1.4±0.1 grad
6 months	0.8±0.03 cu	0.23±0.08 grad	0.77±0.03 cu	0.5±0.07 grad
12 months	0.95±0.02 cu	0.2±0.01 grad	0.93±0.01 cu	0.25±0.07 grad

Table 3

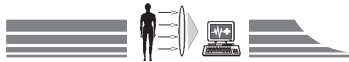
Indicators of body weight load on the injured leg

Observation Terms	The extent of load of the damaged leg, in %	
	Operated with the help of tension band wiring, n=44	Operated by the AO method, n=36
3 months	43±0.3 %	33±0.4 %
6 months	44±0.29 %	40±0.42 %
12 months	48±0.09 %	47±0.1 %

Table 4

Complications after surgical treatment of malleolus fracture

Complications	Operated with the help of tension band wiring, n=44	Operated by the AO method, n=36
Infection, n (%)	1 (2.27 %)	1 (2.77 %)
Implant breakage, n (%)	0	2 (5.54 %)
Late diastasis, n (%)	0	1 (2.77 %)
Loosening, n (%)	0	1 (2.77 %)
Tibiofibular synostosis, n (%)	0	1 (2.77 %)



Conclusions

1. Evaluation of the results using the basometric-device complex, dynamic fixation in the surgical treatment of the malleolar fractures, complicated with tibiofibular syndesmosis injury using tension band wiring in combination with original plates with polyangled screw stability in comparison with AOFAS and OMAS proves that bazometry – stabilometry as an objective way to survey of patients in rehabilitation period, makes it possible to apply this method in clinical practice to control postoperative period and period of rehabilitation in patients with such pathology.

2. Analysis of the ankles fractures, complicated with tibiofibular syndesmosis injury, surgical treatment results, has shown that the dynamic fixation using tension band wiring is preferable than fixation by positional screw, what is confirmed by evaluation of

both conventional scales (AOFAS, OMAS), as well as data of bazometric-stabilometric research.

3. The biggest difference between two methods of surgical treatment is observed in the earlier period (3 months), further to the 12-month difference of clinical and hardware indicators evaluation in both groups is less expressed.

4. Results of the ankles fractures, complicated with damage of TFS, surgical treatment, demonstrate that the use of tension band wiring during fixation of syndesmosis in combination with the original plate for osteosynthesis of the fibula fracture provides reliable fixation, does not require additional surgery and characterized by a minimal number of complications.

Conflicts of Interest: authors have no conflict of interest to declare.

References

- Ahmad, J., Raikin, S. M., Pour, A. E., & Haytmanek, C. (2011) Bioabsorbable screw fixation of the syndesmosis in unstable ankle injuries. *Foot Ankle Int.*, 30(2), 99–105. doi: 10.3113/FAI.2009.0099.
- Andrews, L., & Southgate, C. (2011) Re: Outcomes and complications of treatment of ankle diastasis with tightrope fixation. *Injury*, 41(10), 1096–1097.
- Citak, M., Backhaus, M., Muhr, G., & Kalicke, T. (2011) Distal tibial fracture post syndesmotic screw removal: an adverse complication. *Arch Orthop Trauma Surg*, 131(10), 1405–8. doi: 10.1007/s00402-011-1314-5.
- Johnson, B., Kumar, S., & Sinha, A. (2012). Comparison of outcome following operative fixation of the distal tibiofibular syndesmosis with diastasis screw and suture button techniques. *Injury Extra*, 43(10), 89. doi: 10.1016/j.injury.2012.07.247.
- Kozhemyaka, M. A., Golovakha, M. L., Panchenko, S. P., Kravsovsky, V. L., & Shevelev, A. V. (2015) Modelirovanie fiksacii bercovykh kostej napryazhennymi petlyami pri povrezhdeniyakh mezhercovogo sindesmoza [Modeling of fixing tibia with tight loops in injuries of tibiofibular syndesmosis]. *Ortopediya, travmatologiya i protezirovanie*, 3, 27–35. [in Ukrainian].
- Pelc, H., Carmont, M., Sutton, P., & Blundell, C. (2009). Tight-rope stabilisation of proximal and distal tibiofibular syndesmosis rupture: The floating fibula – A case report. *Injury Extra*, 40(1), 16–18. doi: 10.1016/j.injury.2008.09.016.
- Schepers, T., Lieshout, E.M., Vries, M.R., & Van der Els, M. (2011) Complications of syndesmotic screw removal. *Foot Ankle Int.*, 32, 1040–1044.
- Soin, S. P., Knight, T. A., Dinah, A. F., Mears, S. C., Swierstra, B. A., & Belkoff, S. M. (2009) Suture-button versus screw fixation in a syndesmosis rupture model: a biomechanical comparison. *Foot Ankle Int.*, 30, 346–352. doi: 10.3113/FAI.2009.0346.
- Teramoto, A., Suzuki, D., Kamiya, T., Chikenji, T., Watanabe, K., & Yamashita, T. (2011) Comparison of different fixation methods of the suture-button implant for tibiofibular syndesmosis injuries. *Am J Sports Med.*, 39, 2226–2232.
- Holovakha, M. L., Kozhemiaka, M. A., Shyshka, I. V., & Kryvoruchko, Y. A. (patentee) (2014). Patent Ukrainy na korysnu model №95304 “Prystrij dlia osteosyntezy perelomiv dystalnoho viddilul malohomilkovoi kistky z poshkodzhenniam dystalnoho mizhhomilkovoho syndesmozu” 25/12/14 [Ukraine patent for utility model №95304 Device for osteosynthesis of fractures of the distal fibula with damage of the distal tibiofibular syndesmosis 25/12/14]. *Biuletyn*, 24 [in Ukrainian].
- Holovakha, M. L., & Kozhemiaka, M. A. (patentee) (2015). Patent Ukrainy na korysnu model №103315 “Prystrij dlia khirurhichnoho likuvannia nadsyndesmozykh perelomiv dystalnoho viddilul malohomilkovoi kistky z poshkodzhenniam mizhhomilkovoho syndesmozu” 12/10/15 [Ukraine patent for utility model №103315 Device for the surgical treatment of suprasyndesmosis fractures of distal fibula with damage of the distal tibiofibular syndesmosis 12/10/15]. *Biuletyn*, 23 [in Ukrainian].

Information about authors:

Golovaha M. L., MD, PhD, DSci, Professor, Head of the Department of Traumatology and Orthopedics, Zaporizhzhia State Medical University, Ukraine.

Kozhemyaka M. A., MD, Assistant, Department of Traumatology and Orthopedics, Zaporizhzhia State Medical University, Ukraine, E-mail: doctram@ukr.net.

Maslennikov S. O., MD, Master, Department of Traumatology and Orthopedics, Zaporizhzhia State Medical University, Ukraine.

Відомості про авторів:

Головаха М. Л., д-р мед. наук, професор, зав. каф. травматології та ортопедії, Запорізький державний медичний університет, Україна.

Кожем'яка М. О., асистент каф. травматології та ортопедії, Запорізький державний медичний університет, Україна, E-mail: doctram@ukr.net.

Масленников С. О., магістр каф. травматології та ортопедії, Запорізький державний медичний університет, Україна.

Сведения об авторах:

Головаха М. Л., д-р мед. наук, профессор, зав. каф. травматологии и ортопедии, Запорожский государственный медицинский университет, Украина.

Кожмяка М. А., ассистент каф. травматологии и ортопедии, Запорожский государственный медицинский университет, Украина, E-mail: doctram@ukr.net.

Масленников С. О., магистр каф. травматологии и ортопедии, Запорожский государственный медицинский университет, Украина.

Поступила в редакцию 28.10.2016 г.