

## FEATURES IMPACT NANOSILVER COLLOIDAL SOLUTION ON THE MORPHOLOGICAL AND BIOCHEMICAL PARAMETERS IN RATS

*Alexander Nefodov, Ph.D, Associate Professor,  
Elena Nefodova, MD, Assistant Professor,  
Vera Chatornaya, Doctor of Biological Sciences, Professor,  
Igor Zadesenets, Lecturer of Clinical Anatomy,  
Natalia Onul, MD, Assistant Professor,  
Alexander Halperin, Lecturer in Clinical Anatomy,  
Dnipropetrovsk medical Academy of Ministry of health of Ukraine,  
Larisa Sharavara, Ph.D, Senior Lecturer,  
Zaporozhye state medical University*

**Annotation.** *Modern nanotechnology development and use of nanomaterials is one of the most perspective directions of science and technology of the XXI century. Objective - study the morphological and biochemical parameters influence of colloidal nanosilver solution in the experiment. The experiment was performed on mature white nonlinear rats with weight 180-200 g. During 7 days nanostructured silver solution was administered at a dose of 3.5 mg / kg (concentration of metal at 800 micrograms / ml) intraperitoneally. At the end of the introduction of colloidal nanosilver solution to test animals was carried out blood sampling and conducted morphological study of the effect of nanosilver at the tissue level in parenchymal organs (liver, kidneys, adrenals, brain, heart).*

**Keywords:** *nanosilver, parenchymal organs, biochemical indicators, enzymes.*

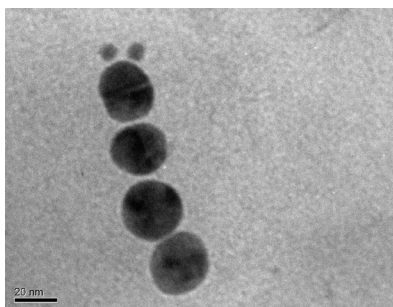
**Introduction.** Modern development of nanotechnologies and using of nanomaterials is one of the most perspective directions of science and technology XXI age [1]. Behavior of matter in a state of nanoparticles open up prospects of materials with new indicators, such as unique mechanical durability, special spectral, chemical and biological characteristics. Among the existing metal nanoparticles deserve special attention nanoparticles of gold and silver. This significant interest is caused by perspective of using nanometals in technologies of design highly effective diagnostic tools and targeted therapy, particularly for cancer. Significant attention of investigators is mainly focused on the study of the biological effects of nanoparticles of gold and silver at the cellular level. Regarding the biochemical effects of exposure to eukaryotic cells, there are only a few data on the impact of inhibitory nanogold with average size 9 nm on the activity of cytochrome P450 isoenzymes [2]. Silver nanoparticles have a number of different pharmacological effects. Chief among them is antimicrobial. Nanosilver due to the small size and other physical and chemical properties is extremely active and causes the death of microorganisms: bacteria, viruses, pathogenic fungi. The use of silver in the form of nanoparticles can significantly reduce the concentration of silver preserving antimicrobial properties, including microorganisms resistant to antibiotics.

For example, current research action colloidal silver ions have shown that they have a strong ability to neutralize viruses of smallpox vaccine, some strains of influenza virus, entero- and adenoviruses. Other significant effects of nanosilver are anti-inflammatory and immunomodulatory. These effects are associated with inhibition of the synthesis of cytokines such as TNF- $\alpha$ , IL-12, IL- $\beta$ , matrix metalloproteinases and, in particular, MMP-9. Moreover, silver ions are involved in metabolic processes. Under the influence of silver increases twice the intensity of oxidative phosphorylation in the mitochondria of the brain and increases the concentration of nucleic acids that improves brain function.

Interest in the development of products based on nanostructured silver grows. It is associated with pharmacological properties that this metal shows at nanoscale level.

**Purpose of work** - to study morphological and biochemical parameters of influence nanosilver colloidal solution in the experiment.

**Material and methods.** Nanosilver colloidal solutions were used on models in the experiment. These solutions were obtained by the original method in Institute of Biocolloidal Chemistry. F.D.Ovcharenko NAS of Ukraine (Director: Doctor of Chemistry, Professor Ulberh ZR). Silver nanoparticles (aqueous colloidal solution): initial substances from which drug is synthesized are: silver nitrate, potassium carbonate, tannin, water. The form of nanoparticles is spherical (Fig. 1). The initial concentration of the drug nanoparticles of silver is 800mkh / ml for metal. The size of silver nanoparticles according to laser correlation spectroscopy is (ZAve)  $29,9 \pm 0,6$  nm.



*Fig. 1. The shape and size of silver nanoparticles. Visualization of nanoparticles in colloidal solutions was performed by confocal microscopy (LSM 510 META «Carl Zeiss», Germany).*

Colloidal silver solutions with systemic administration are accumulated most of all in the brain, liver and endocrine glands. Silver, as a heavy metal, is toxic due to the fact that it can as bivalent cation, compete in the active centers of the enzyme and protein with biogenic elements, such as copper. As a result, the metabolism of the whole organism is changed. Therefore, these aspects was paid attention in biochemical and morphological studies.

The experiment was carried out on white mature nonlinear rats with weight 180-200 g. The animals were kept on a standard diet of the vivarium SE «DMA» [3, 4, 5]. Research was carried out under the agreement on scientific and technical cooperation

between the National Medical University of A.A. Bohomolets, Research Institute of Nanotechnology and resource-saving of Ukraine and the State institution «Dnipropetrovsk medical academy Ministry of Health of Ukraine.» Animal experiments were performed according to the guidelines of SPC Ukraine (2001), «General ethical principles of animal experiments» adopted by the first National Congress on Bioethics (Kyiv, 2001), the requirements of the European Convention for the Protection of laboratory animals (Strasbourg, 1986), «Regulations on the use of animals in biomedical experiments» [5].

During 7 days nanostructured silver solution was administered at a dose of 3.5 mg / kg (metal concentration of 800 micrograms / ml) intraperitoneally. The control group received saline at the dose of 0.1 ml / 100 g body weight. Upon expiration of the administration of colloidal solution of nanosilver to the experimental animals, blood sampling and determination of these indicators of plasma was carried out: alanine aminotransferase (ALT), asparagine aminotransferase (AST), superoxide dismutase (SOD), catalase, alkaline phosphatase (ALP), ceruloplasmin (CP), lactate dehydrogenase (LDH), urea, creatinine, total protein (TP) and glucose [3, 6, 7, 8, 9]. The results were compared with the results of the control group.

Morphological study. Experimental animals were kept in plastic cages, 8 animals were in one unit. Rats received a standard diet of vivarium with free access to water. Two groups of animals were randomly formed: experimental and control. Laboratory animals were taken out of the experiment by decapitation under light ether anesthesia. The studied organs (liver, kidneys, adrenal glands, brain) were isolated and fixed in 10% neutral formalin. Standard methods for preparation of histological specimens were used. Slices with thickness of 8 - 10 microns were stained with hematoxylin-eosin. Specimens were studied under the microscope «Biolam» [3].

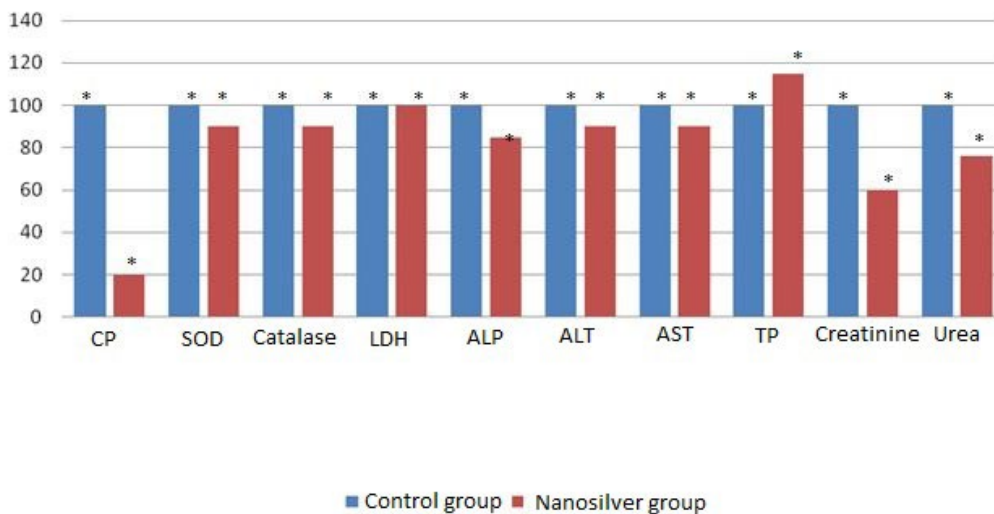


Fig. 2. Change of plasma biochemical parameters after 7 days administration nanosilver colloidal solution.

Note. \* -  $P < 0.05$  compared with control.

The experimental results were processed by licensed software STATISTICA 6.1., Software StatPlus 2006, OriginPro 7.5 (OriginLab Corporation, USA), Microsoft Excel 2003. Mathematical processing included calculations of the average value (M), their errors ( $\pm m$ ). Authentication of intergroup differences, according to experiments, conducted using parametric Student's t-test, Wilcoxon Rank-Sum test, Mann-Whitney test and method of univariate analysis of variance (ANOVA) [10, 11, 12, 13]. The difference was considered statistically significant at the level of  $p < 0.05$ . Before using parametric criteria was audited hypothesis of normal distribution of random variables (by the criteria Kolmogorov-Smirnov adjusted Lillifors and Shapiro-Wilkie).

### **Results and discussion.**

The obtained data of our experimental studies are shown in Fig. 2.

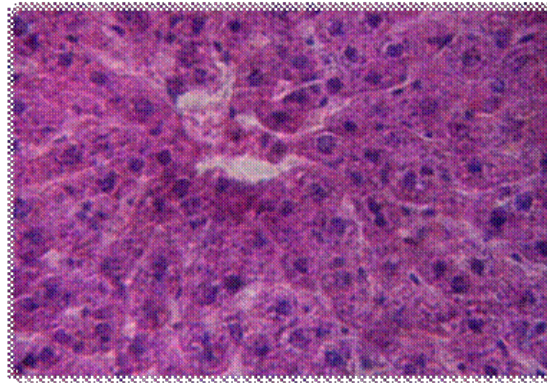
The activity of Ceruloplasmin in plasma was reduced by 80.0% ( $P < 0.05$ ) compared with control group. Most likely that nanosilver can replace copper ions in a molecule of CP. These results suggests that nanosilver is a potential anti-inflammatory agent. Also nanosilver anti-inflammatory effect was observed in histamine and korahinine models of inflammation. However, LDH activity was the same as in experimental and in the control group.

The experimental animals had reduced levels of: creatinine by 40.0% ( $P < 0.05$ ); Urea by 24.0% ( $P < 0.05$ ) compared with control. We can assume that nanostructured colloidal silver solution inhibits renal enzymes (Succinate dehydrase) such as mercury diuretics and furosemide. Reducing blood level of creatinine may be associated with decreasing production of creatinine by muscles and increased creatinine excretion (by increasing glomerular filtration rate). At the test animals blood plasma level of ALT and AST activity were reduced by 8.0% ( $P < 0.05$ ), respectively, SOD and catalase 10.0% ( $P < 0.05$ ) for each metric, alkaline phosphatase by 15.0 % ( $P < 0.05$ ) compared with the control group, that corresponds to the biological standards for enzymes.

The level of total protein and glucose in plasma was increased by 15.0% ( $P < 0.05$ ) relatively to control, that indicates common metabolic well-being of the body.

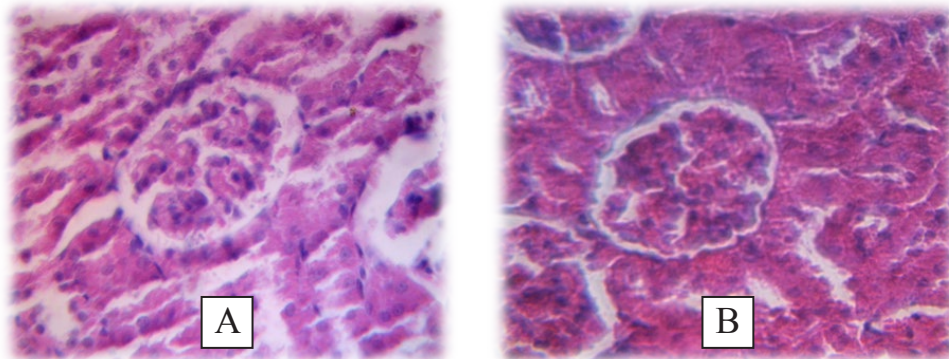
We carried out morphological study on the effects of nanosilver at the tissue level in parenchyma organs and blood vessels.

Experimental studies of the functional state of epithelial and connective tissue such vital organs as the liver, are significant condition in identifying of the influence of new drugs on the organism. Since the harmful effects of substances and associated abuse of physiological regeneration turn on a mechanism that increases reproductive processes in the liver. Therefore dystrophy and reparative degeneration considers as two opposite deviations of physiological regeneration from its normal course. In our experiment in each group we didn't observe any degenerative changes or signs of reparative regeneration. In general, architectonic body is preserved, there were found single cases of liver beam discomplectation, seldom hemorrhages were observed. The inner, middle and outer membrane of the veins and arteries were not altered, hepatocytes had normal shape. These characteristics were observed for all groups of test animals and control. As a result of our study was revealed unequivocal and same reaction of liver cells of experimental animals at influence all doses of study drug (Fig. 3).



*Fig. 3. histological sections of rat liver of experimental group. Colors - hematoxylin-eosin. Zoom 7x40.*

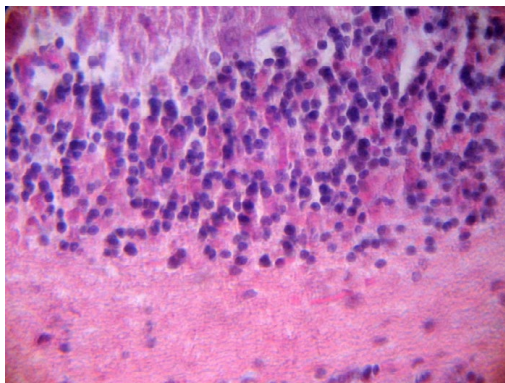
In specimens kidney in control and experimental groups are clearly visible capsule, medullary and cortical layers. In cortical layer are seen renal corpuscles that have a spherical shape with a slightly rough surface. Mostly renal corpuscles are shriveled. It is non-specific reaction to the drug. The space between renal corpuscles is represented by a numerous round-shaped slices of convoluted tubules and vessels of cortex without visible changes. Tubular epithelium is unchanged in all groups and tightly adjoins to the surface of the basement membrane. Medulla is presented by homogeneously colored parenchyma, that is located in parallel with tubular apparatus and has a typical structure (Fig. 4).



*Fig. 4. histological sections of rat kidneys control (A) and experimental (B) groups. Colors - hematoxylin-eosin. Zoom 7x40.*

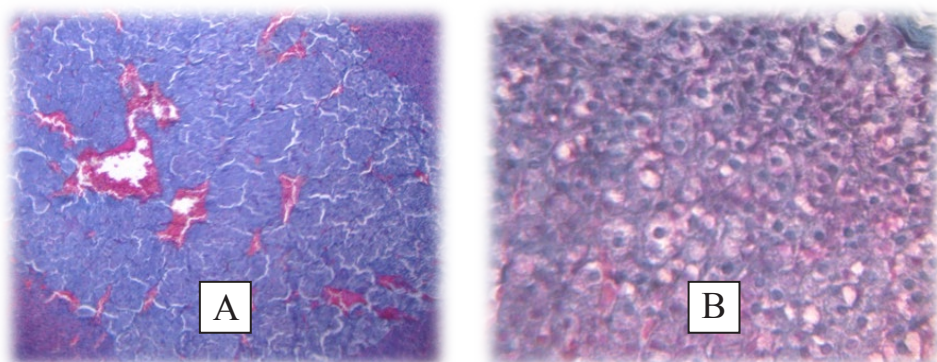
Macroscopically brain membrane has normal color with no signs of hemorrhage, edema, or swelling of the brain tissue. In histological preparations cells have normal shape and orientation. Perivascular swellings, swellings between cells, degenerative changes in the cells are absent. Glia cells are without evidence of a pathology (Fig. 5).





*Fig. 5. histological sections of rat brain of experimental group. Colors - hematoxylin-eosin. Zoom 7x40.*

Histological experimental study of specimen of adrenal glands of studied groups has shown that there are no any pathological changes. All areas of cortex are clearly expressed, connective tissue capsule is not thinned, defibrination is not observed. Glomerular area, which is located under capsule, consists of cells that remain mainly arch-like groups of cells. The cells are located between vessels, which have native structure. From the dense connective capsule in the cortex are given off many thin layers that form the stroma of the gland (Fig. 6).



*Fig. 6. histological sections of medullary (A) and cortical (B) layers of rat adrenal gland of experimental group. Colors - hematoxylin-eosin. Zoom 7x40.*

Under the capsule there is the cortex. There are three areas: external glomerular formed with small rounded cells, then deeper goes zona fasciculata, there are situated larger cells, the third zone of the cortex - zona reticularis. Medulla is formed by a dense network of cellular strands that intertwine with wide sinusoidal capillaries (Fig. 6).

In the study of histological sections of the heart of the rats in the nanosilver group, the normal structure of the ventricles, atrium and interventricular septum was determined. In general, the compact myocardium was physiologically developed, the

papillary muscles and the internal relief of the ventricles of the heart correspond to the normal, the cavities of the chambers of the heart are not enlarged, the development of the aorta and pulmonary trunk is not disturbed, changes of the microhemetic-circulatory circulation are not revealed.

**Conclusions.** Summarizing received data we can make the following conclusions:

1) nanostructured silver is less toxic to the organism, than simple silver salts is (according to the literature);

2) From received data we can suggest that nanosilver besides antimicrobial activity, reveals an expressed anti-inflammatory activity and possible diuretic effect.

3) In our experiment in each group we didn't observe any degenerative changes or signs of reparative regeneration in the liver. In general, architectonic of the organs is preserved, there were found single cases of liver beam discomplectation, seldom hemorrhages were observed. The inner, middle and outer membrane of the veins and arteries were not altered, hepatocytes had normal shape. There were no pathological changes in the adrenal glands. Based on data obtained during the morphological study of taken specimens, we can conclude that represented changes of the structure of the tissues are not caused by the administration of nanosilver.

**Prospects for further researches.** Relevant and timely is further more detailed study of the impact of nanosilver colloidal solution in combination with drugs.

**Conflict of interest.** Absent.

### References:

1. Shatorna V.F., Harets' V.I., Nef'odova O.O., Chekman I.S., Kaplunenko V.I. (2016). The role of metal nanoparticles citrate in search of new bio antagonists embryo toxicity of lead acetate. Dnipropetrovsk, «Serednyak», 118 p.

2. Shatorna V.F., Chekman I.S., Harets' V.I., Nef'odova O.O., Kaplunenko V.I. (2017). Experimental study on the impact of nanometals on embryogenesis and development of heart. Integrative antropology, 1 (29), P. P. 59-63.

3. Stefanov O. V. [Preclinical studies of drugs: guidelines]. Kiev : Avitsena, 527 p.

4. Zapadnyuk I. P., Zapadnyuk V. I., Zahariya E. A., Zapadnyuk B. V. (1983). [Laboratory animals. Breeding, content, use in experiment]. Kiev : Vysshaya shkola. General publishing, 383 p.

5. Kozhem'yakin Yu. M., Khromov O. S., Filonenko M. A., Sayretdinova H. A. (2002). [Scientific - practical advice on keeping laboratory animals and to and from them]. Kiev, 155 p.

6. Goryachkovskiy A.M. (1994). [Reference book on clinical biochemistry]. Odessa, 160-255 p.

7. Korolyuk M.A. (1988). Method for determination of catalase activity. Laboratornoe delo, 1, P. 16-19.

8. Kochetkov G.A. (1980). [Practical Guide. Enzymology]. Moscow : Vysshaya shkola, 272 p.

9. Chevari S., Chaba I., Sekey Y. (1988). The role of superoxide dismutase in oxidative processes of cells and methods of its determination in biological material. *Laboratornoe delo*, 11, P. 678-681.
10. Lakin G.F. (1990). [Biometrics]. Moscow : Vysshaya shkola, 293 p.
11. Lapach S.N., Chubenko A.V., Babich P.N. (2001) [Statistical methods in biomedical research using EXCEL]. Kiev : Morion, 408 p.
12. Mintser O.P., Ugarov B.N., Vlasov V.V. (1982) [Methods of processing medical information]. Kiev : Vyshcha shkola, 160 p.
13. Strelkov R.B. (1986) Statistical tables for accelerated quantification of the pharmacological effect. *Pharmacology and toxicology*, 4, P. 100-104.